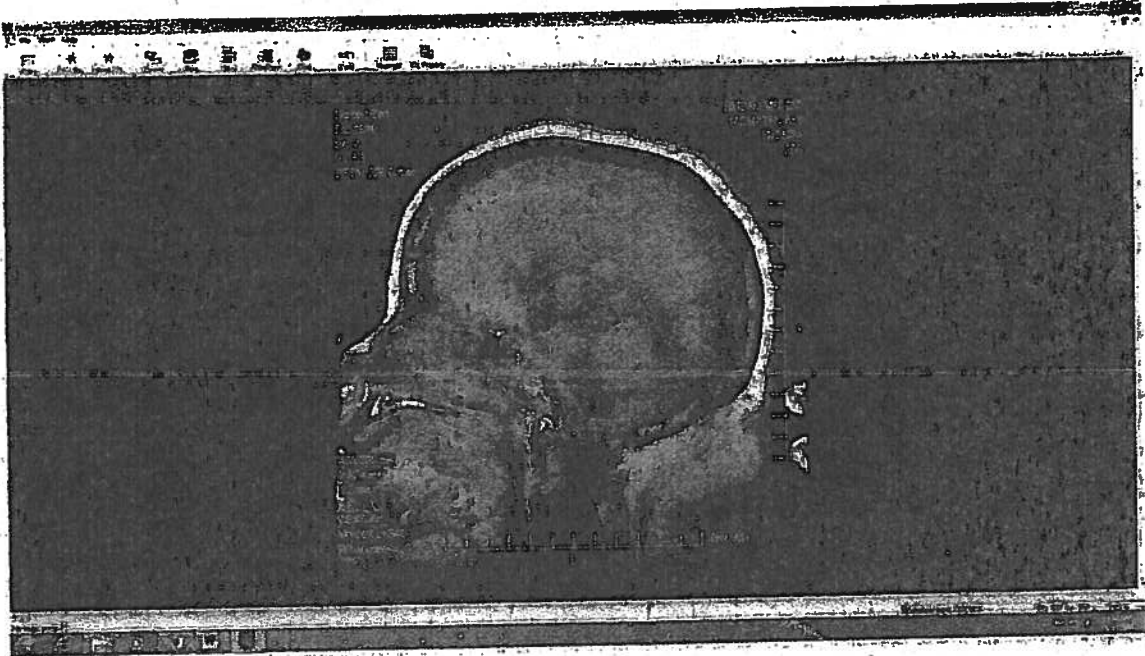


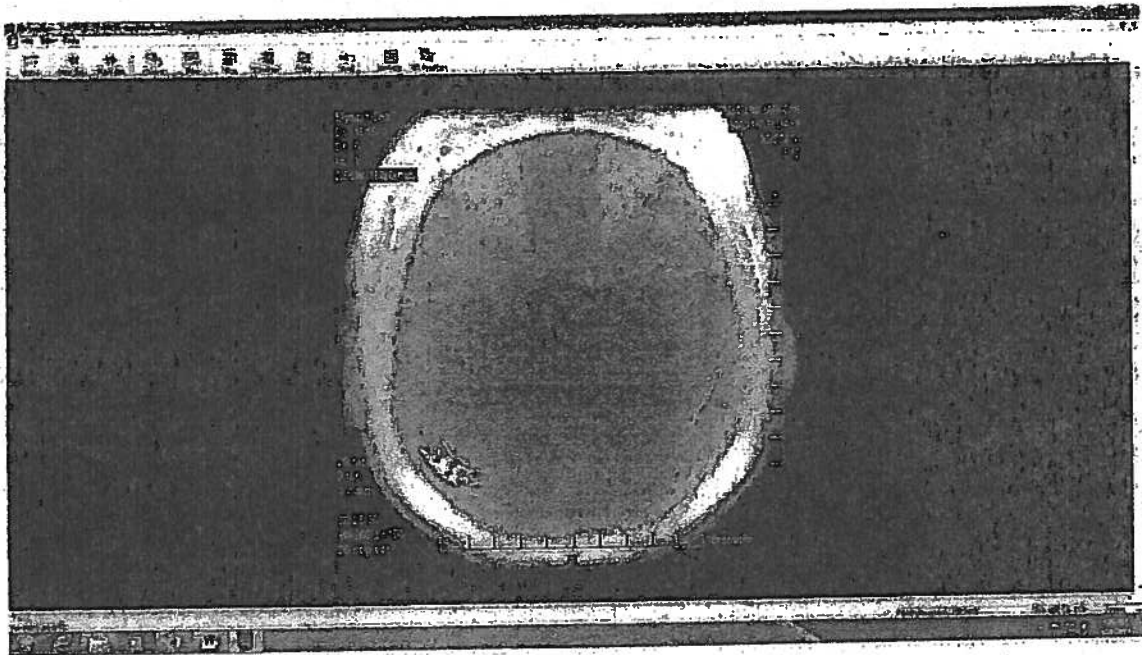
## MRI STUDY OF THE BRAIN

This is a preliminary report. The patient was studied with all conventional sequences (T1, T2 in different axis, MRA, Fractional Anisotropy, et.), which will require off-line processing to calculate tractography and other important measurements.

In this axial sequence, although it is possible to see spread lesions throughout the whole brain, like a huge lesion at the pons, and a destruction of the corpus callosum, I call your attention to the fact that it is possible to observe ribbons at the level of the cortex, indicating preservation of neocortex. Had she been brain dead without cerebral blood flow since January of 2014 we would not expect to see the structure of the brain to be as it is, it would have, most likely, liquefied.




In this MRA sequence, it is possible to show slow but intracranial cerebral blood flow.



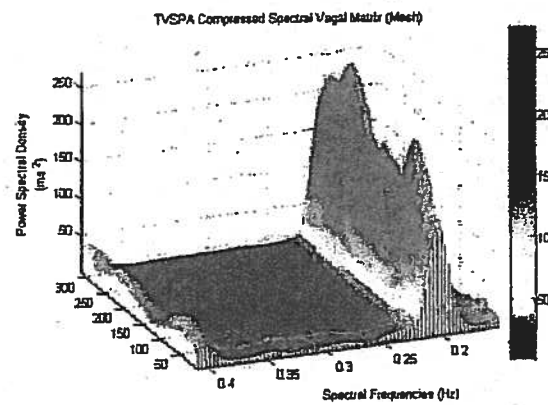
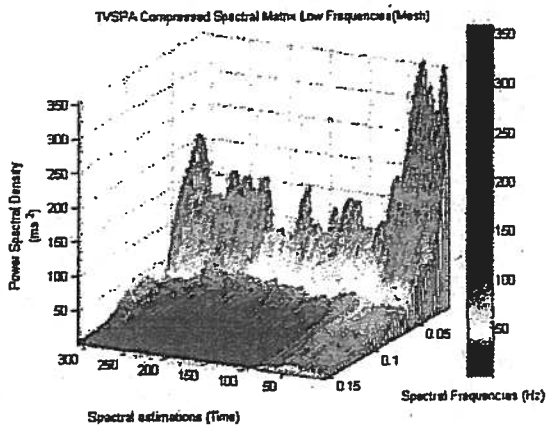
## HEART RATE VARIABILITY

In these two panels HRV spectral analysis is shown and compared in a brain-dead case (left) and in the patient (right). It is easy to observe that in the brain-dead case there is only a remaining peak which corresponds with the frequency of the ventilator. Nonetheless in the patient (right), there are remaining spectra in the very low (VLF), low frequency (LF), and median frequency (MF) bands, and also the frequency of the ventilator is present, but it is possible to observe modulations of amplitude in this peak, which do not only correspond with the ventilator effect.

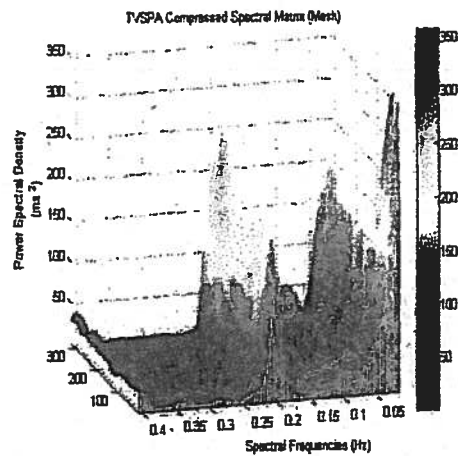
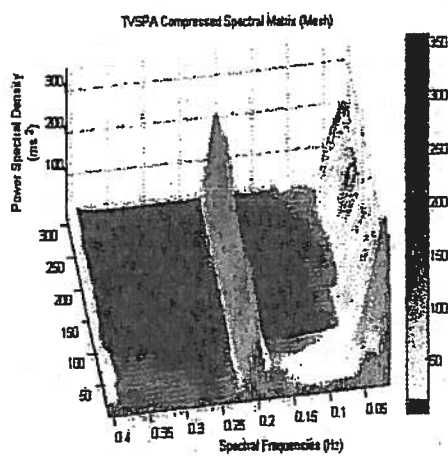


HRV SPECTRAL ANALYSIS IN BD

HRV SPECTRAL ANALYSIS IN THE PATIENT



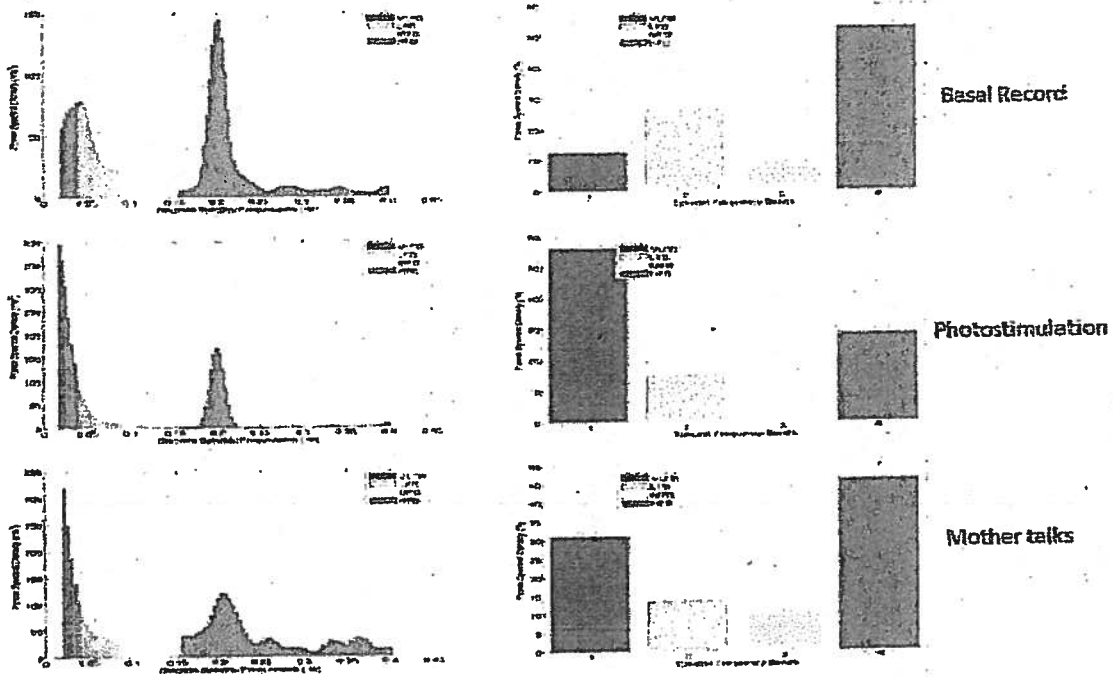
In the HRV spectra (above), in the left panel it is possible to affirm the presence of the VLF, LF, and MF. In the right panel it is observed high frequencies (HF) corresponding to the peak of the ventilator, but it is possible to observe modulations of amplitude in this peak, which does not correspond only with the ventilator effect.



In the HRV spectra (above), both in the left and right pannels, it is possible to affirm the presence of all bands: VLF, LF, MF, and HF.

In this next figure we show the dynamic changes of the HRV spectra during three experimental conditions: Basal Record, Photostimulation, and "Mother talks to the patient"

It is possible to affirm that there are clear dynamic changes when comparing the three different conditions, indicating an effect of these stimuli to the modulation of the central autonomic nervous system.



## **CONCLUSIONS OF THE REPORT**

### **A- EEG RECORD**

- The neurophysiological data is not consistent with the classical EEG isoelectric pattern found in brain-dead cases.
- Although there were EKG in derivations, I can appreciate the presence of low voltage EEG true activity.
- Although the EEG records show the presence of some artifacts, due to patient head and body movements of electrodes, I can see the existence of EEG activity with a prevalence of diffuse Delta, with superimposed activity within the Alpha and low Beta ranges.
- Some intermittent Delta and Theta activity is present in a random pattern. The Technologist assured that the electrodes did not have any contact with the ventilator hoses, which might account for artifacts simulating EEG activity.
- In conclusion, the neurophysiological data derived from this assessment, confirms the preservation of true EEG bioelectrical activity in this case.

### **B- MRI STUDY OF THE BRAIN**

The MRI sequences show preservation of intracranial structures and the MRA shows a diminished, but present intracranial cerebral blood flow (CBF). Considering the concept of brain death (BD), that per definition an irreversible absence of CBF should be present, in this case with more than 9 months of evolution with the possible diagnosis of BD, I would have expected to find the classic description of the "respirator brain" (brain liquefied, without any nervous system structure, etc.). Although recently Eelco Wijdicks et al. described that there is no specific anatomopathology findings in brain-dead cases, and that "respirator brain" no longer exists in BD, this is due to the fact that diagnosed brain-dead cases are usually kept under respirator for hours or a few days, prompted by organ retrieval protocols, or because life support is removed.

### **C- HEART RATE VARIABILITY**

Although this methodology is not usually included as an ancillary tests in BD confirmation, many reports have recently appear proposing HRV as a powerful tool to assess the central nervous system in comatose and brain-dead patients.

With the results I have reviewed, it is possible to affirm that this patient shows remaining autonomic activity modulated in the brainstem. Moreover, the dynamic changes we found comparing the three different experimental conditions, show an emotion-content

component when the mother talks to the patient. This **CANNOT** be found in a brain-dead patient.

#### **GENERAL CONCLUSION**

I am a defender that brain death means death of the individual, and it is an irreversible state. I can also affirm as a Corresponding Fellow of the American Academy of Neurology (AAN), that the AAN Criteria for BD diagnosis are without any doubt, one of the most complete guidelines in the world. Hence, a case who fulfills the AAN brain criteria is brain-dead, and then is dead.

I was not involved in the initial evaluation of this case, and hence I **CANNOT** give any opinion about the diagnostic procedure. I can only affirm that with the documents presented to me **NOW**, as a volunteer worldwide expert on the field of brain death, I **CAN AFFIRM THAT THIS PATIENT DOES NOT ACTUALLY FULFILL THE BD CRITERIA, AND HENCE HE/SHE IS NOT BRAIN-DEAD.**

My best,

**CALIXTO MACHADO, MD, Ph.D., FAAN**  
Corresponding Fellow of the American Academy of Neurology  
President  
**CUBAN COMMISSION FOR THE DETERMINATION OF DEATH**  
**CUBAN SOCIETY OF CLINICAL NEUROPHYSIOLOGY**  
Instituto de Neurología y Neurocirugía  
La Habana 10400  
Tel.: **537-200-1111**  
E-mail: **[REDACTED]**

Patient's Name: *Jahi McMath*

**International Brain Research Foundation**

**Patient's Info:**

Name: *Jahi McMath*

Date of observation: *09/01/2014*

Date of Birth (age): [REDACTED]

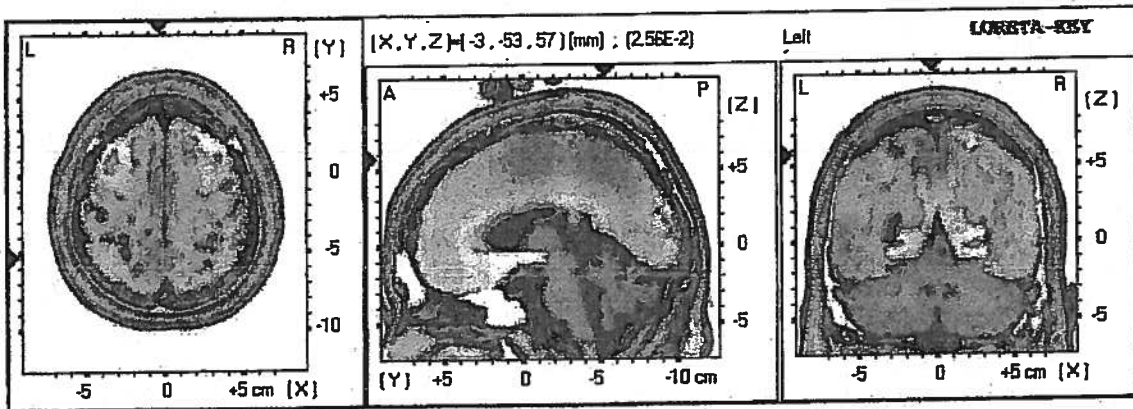
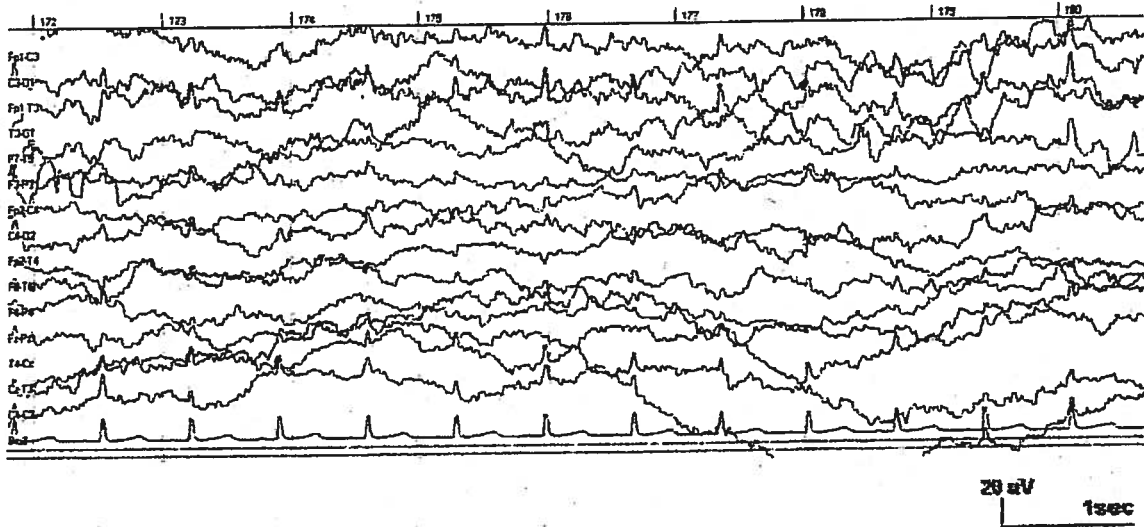
Gender: *F*

**EEG/ERP recording requirements and procedure:**

- **EEG/ERP Equipment:** The EEG/ERP recordings were done with the Mitsar amplifiers (Mitsar-EEG-10/70-201), 21 EEG channels.
- **EEG/ERP Recording and Analyzing software:** "WinEEG"
- **ERP stimulus presentation software:** "Psytask"
- **Electrode placement:** EEG/ERP was recorded from 19 scalp locations according to the International 10/20 system (*Apendix-1*).
- **Montage:** (*see Apendix-2*).
- **Interelectrode impedances:** under 10,000 ohms but over 100ohms.
- **Sampling rate:** 500 Hz.
- **Sensitivity** increase up to 2 uV/mm during most of the recording to distinguish ECS low-voltage output EEG.
- **Time constant** of 0.3-0.4 second (0.53 Hz).
- **Filters:** High Cut: 30 Hz, Notch Filter: 55-65 Hz.
- **Frequency Ranges:** *Delta:* 1.5-4 Hz; *Theta:* 4-7.5 Hz; *Alpha:* 7.5-14 Hz; *Beta1:* 14-20 Hz; *Beta2:* 20-30 Hz; *Gamma:* :30-40 Hz.
- "Bio3" channel =EKG



1. Fragment-1



Value= 9.99E+1

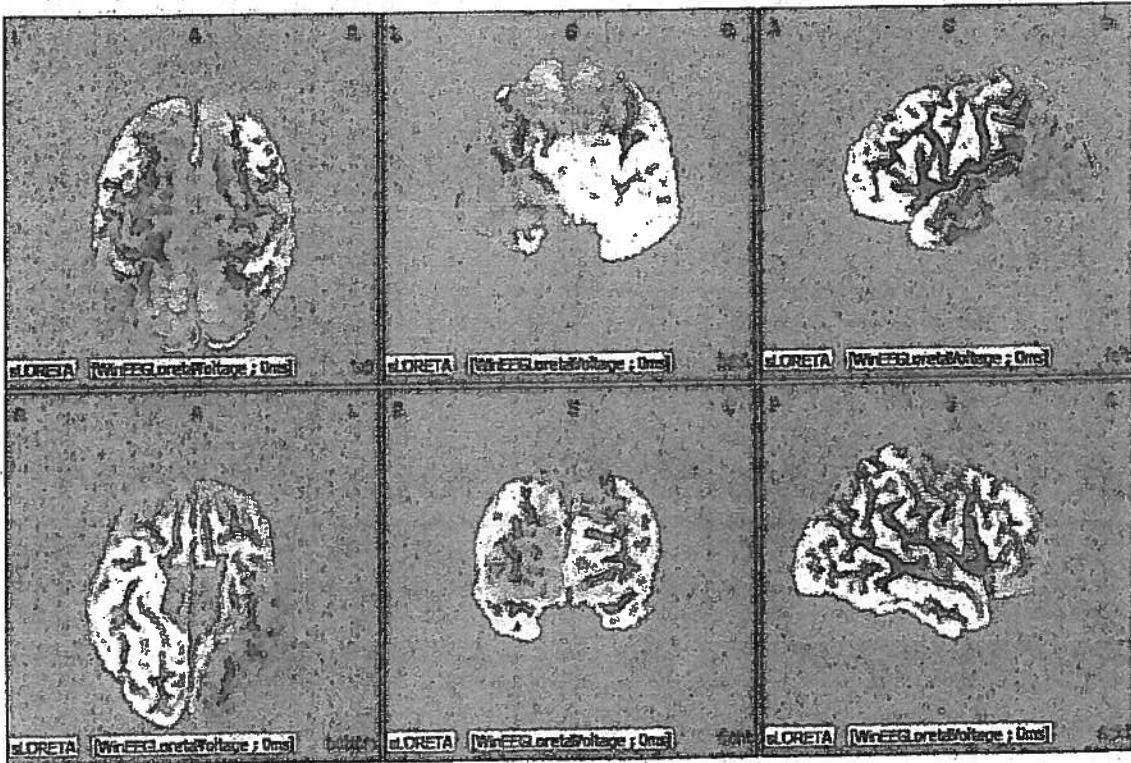
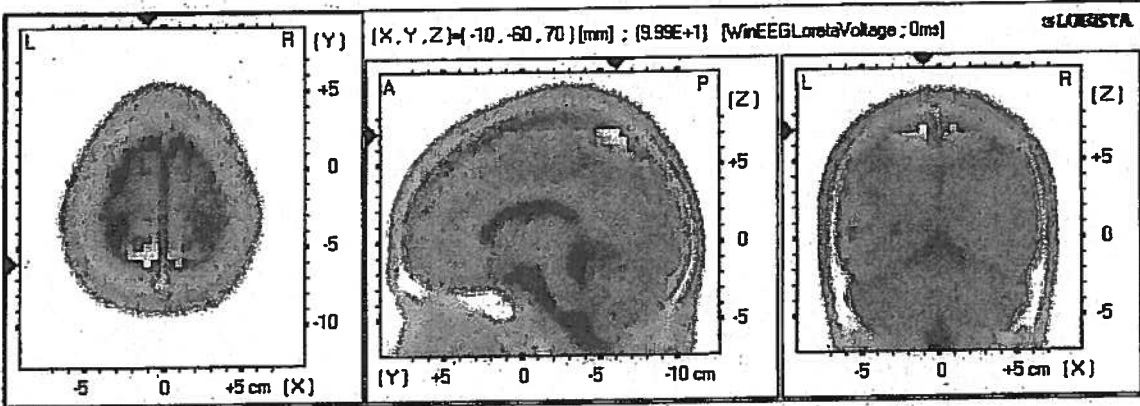
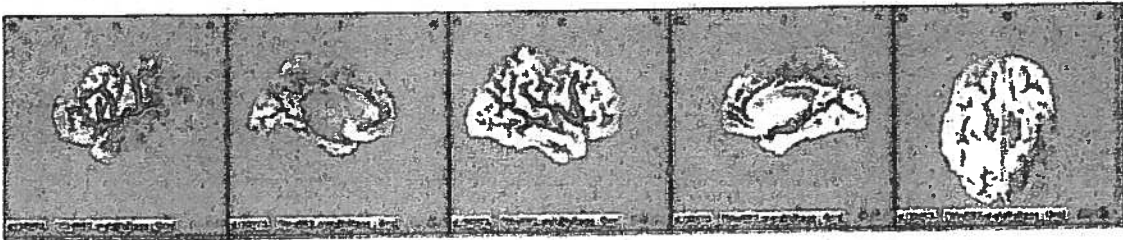
(X= -10 , Y= -60 , Z= 70) (MNI coords)

Best Match at 0 mm

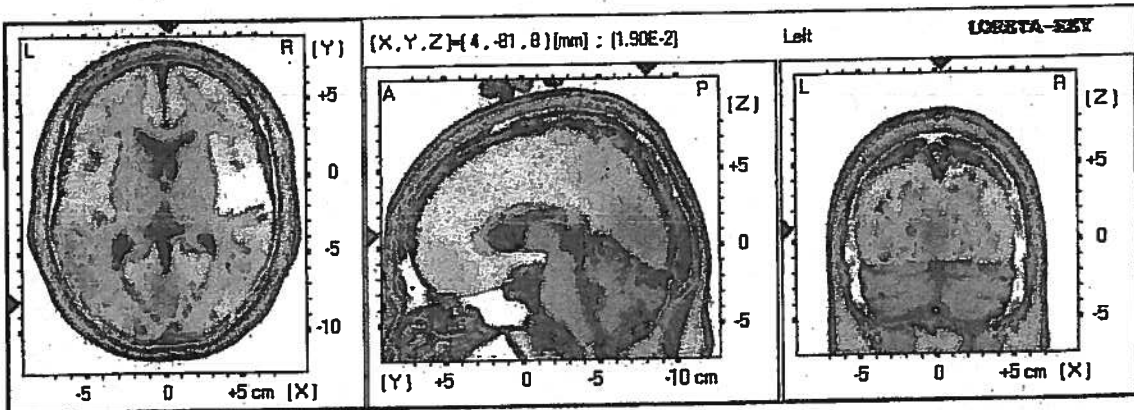
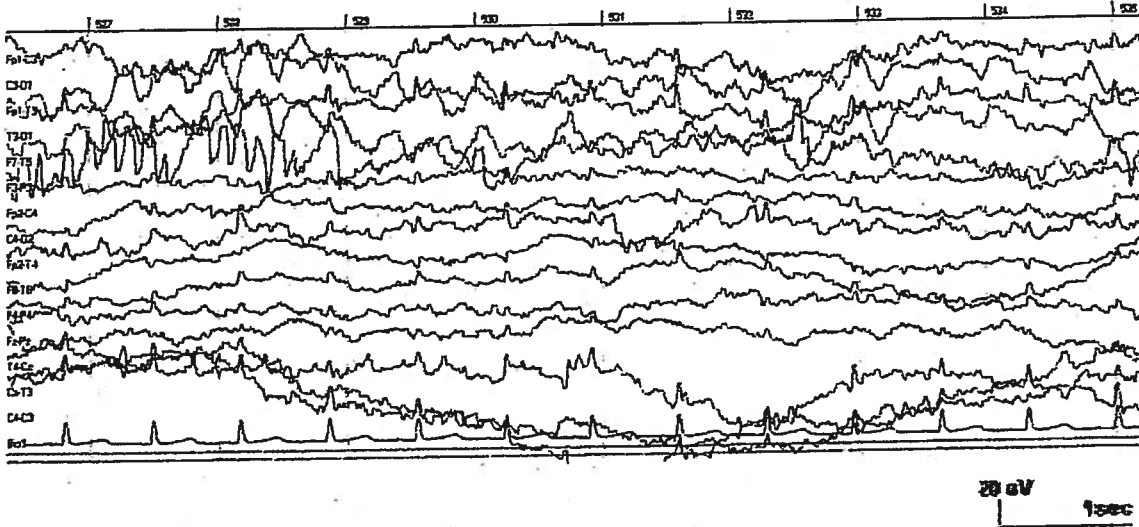
Brodmann area 7

Postcentral Gyrus

Parietal Lobe



## 2. Fragment-2



Value= 4.14E+1

(X= -20, Y= -100, Z= -10) (MNI coords)

Best Match at 0 mm

Brodmann area 18

Lingual Gyrus

Occipital Lobe